

Acute angle closure as an atypical presentation of ocular cysticercosis, a case report

María Isabel Pérez-Palacio^{1,*}, Jorge Rafael Méndez-Marulanda², Camilo Eduardo Martínez-Sánchez³

Abstract

Ocular cysticercosis is an endemic disease in developing countries with diverse clinical presentations depending on the cyst location. We highlight a case of subretinal intraocular cysticercosis that presented with acute angle closure, an atypical clinical presentation. The initial treatment involved medical therapy with albendazole, oral steroids, and ocular hypotensive agents. During follow-up, despite symptom control and ocular hypertension, a significant intraocular inflammatory reaction was identified, requiring surgical management. The patient underwent pars plana vitrectomy with favorable anatomical and visual outcomes. This case emphasizes the importance of recognizing atypical clinical presentations to promote timely diagnosis and treatment and suggests that cyst size may influence the inflammatory response and the decision between medical or surgical management.

Keywords: Cysticercosis; ophthalmology; ocular hypertension; ultrasonography

Cierre angular agudo como una presentación atípica de cisticercosis ocular, un reporte de caso

Resumen

La cisticercosis ocular es una enfermedad endémica de países en vías de desarrollo, con presentaciones clínicas diversas según la localización del quiste. Se destaca un caso de cisticercosis intraocular subretiniana que debutó con un cierre angular agudo, una presentación clínica atípica. El tratamiento inicial involucró terapia médica con albendazol, esteroides orales e hipotensores oculares. En el seguimiento, a pesar del control de la sintomatología y la hipertensión ocular, se evidenció una importante reacción inflamatoria intraocular que requirió manejo quirúrgico. Se realizó una vitrectomía vía pars plana con un desenlace anatómico y visual favorable. Este caso resalta la importancia del reconocimiento de presentaciones clínicas inusuales para favorecer el diagnóstico y tratamiento oportuno, y sugiere que el tamaño del quiste puede influir en la respuesta inflamatoria y en la elección del manejo médico o quirúrgico.

Palabras clave: Cisticercosis; oftalmología; hipertensión ocular; ecografía.

Introduction

Cysticercosis is a parasitic infection caused by the larval form of *Taenia solium*. It is an endemic clinical entity in Africa, India, Asia, Mexico, and Latin America, where poor sanitary conditions facilitate transmission¹. The most frequently affected sites are the subcutaneous tissue (24.5%), followed by the brain (13.6%) and the eye (10.8%)¹. Owing to its high vascular density, the eye is the primary organ affected¹. The disease primarily affects individuals between 20 and 50 years of age, with a higher prevalence in males according to some studies^{1,2,3}. In Colombia, between 2009 and 2013, the reported incidence of ocular cysticercosis was 0,19/100,000 cases⁴.

From an ophthalmological perspective, cysticercosis can present with extraocular or intraocular involvement. Extraocular involvement is more common in Eastern countries, whereas intraocular cases are more frequently reported in Western regions². Intraocular cysticercosis typically manifests as painless visual acuity decline and, to a lesser extent, myodesopsia^{2,3}. However, atypical presentations can occur, as highlighted in this case of subretinal intraocular cysticercosis presenting with acute angle closure, a rare manifestation.

Early diagnosis in such atypical cases can be difficult; however, the use of diagnostic aids such as ocular ultrasound or computed tomography may be the key to diagnosis owing to their

1 Pontifical Xavierian University, Bogotá, Colombia. <https://orcid.org/0000-0002-0289-6440>

2 Pontifical Xavierian University, Bogotá, Colombia. <https://orcid.org/0000-0002-8073-9926>

3 Pontifical Xavierian University, Bogotá, Colombia. <https://orcid.org/0000-0003-1706-7765>

* Autor para correspondencia:
Correo electrónico: misabelperezp@javeriana.edu.co

Recibido: 18/10/2024; Aceptado: 24/06/2025

Cómo citar este artículo: M.I. Pérez-Palacio, *et al.* Acute angle closure as an atypical presentation of ocular cysticercosis, a case report. *Infectio* 2025; 29(4): 248-251
<https://doi.org/10.22354/24223794.1254>

typical presentation patterns. Treatment may involve antiparasitic therapy, corticosteroids, or a surgical approach, depending on the severity and response to medical management.

Case description

A 51-year-old male, with no pertinent past medical history, presented to the emergency department with acute deterioration in visual acuity in the right eye associated with redness, pain, ipsilateral headache, and emetic episodes. The initial ophthalmological examination revealed a best-corrected visual acuity of counting fingers in the right eye (OD) and 20/20 in the left eye (OS) with anisocoria due to non-reactive mydriasis in the right eye (Fig. 1a). The extraocular motility was normal. The anterior segment examination showed no abnormalities in the left eye, while the right eye demonstrated an asymmetric narrow anterior chamber compared to the contralateral eye, with a closed chamber angle on gonioscopy and intraocular pressure of 28 mmHg in the OD and 12 mmHg in the OS, following a dose of 500 mg of oral acetazolamide administered by the emergency department.

Fundus examination was normal in the left eye; however, in the right eye, an inferior hemorrhagic retinal detachment was noted, with macular involvement and the appearance of a subretinal mass. Ocular ultrasound was performed, identifying in B-mode a subretinal cystic lesion approximately 7 mm in diameter, which in A-mode showed a peak of high reflectivity inside, suggestive of a scolex, findings consistent with a case of ocular cysticercosis (Fig. 1b and 1c). A complementary cranial computed tomography scan ruled out central nervous system involvement (Fig. 1d). The patient denied eating raw or uncooked foods or visiting or living outside the city.

In consultation with the patient, considering the size of the lesion, the posterior location, and the potential morbidity associated with surgical intervention, medical management was initiated with albendazole at a dose of 15 mg/kg/day divided into two doses, along with steroid treatment with oral prednisolone at a dose of 1 mg/kg/day. Topical hypotensive management was added with timolol 0.5% / dorzolamide 2% / brimonidine 0.2%, one drop every 12 hours in the right eye. On follow-up assessment one week later, the intraocular pressure was adequately controlled (14 mmHg), pain was modulated, and visual acuity was stable; however, the patient developed significant cellularity in the vitreous cavity (Fig. 1e). The patient underwent surgery, where pars plana vitrectomy was performed with a transvitreal approach via retinotomy and using silicone oil as a tamponade, achieving successful retinal reattachment.

Discussion

Cysticercosis is an endemic clinical entity in Africa, India, Asia, Mexico, and Latin America, with the eye being one of the primary organs affected because of its high vascular density¹. It primarily affects individuals between 20 and 50 years of age, with a higher prevalence in males according to some studies^{1,2,3}.

Cysticercosis is a parasitic disease caused by *Cysticercus cellulosae*, the larval stage of *Taenia solium*. Humans acquire the infection through the ingestion of eggs from contaminated food or water. The larvae penetrate the intestinal wall, migrate via the bloodstream, and develop into cysts in various tissues, including the eye. Ocular cysticercosis can cause significant visual impairment, depending on the cyst location and immune response¹.

Ophthalmic clinical presentations can be divided into extraocular forms, involving extraocular muscles, subconjunctival space, optic nerve, and appendages, which are more commonly seen in Eastern countries, and intraocular variants, which, in order of frequency, affect the intravitreal space, subretinal space, and anterior chamber, representing 7.73%, 3.77%, and 1.43% of reported ocular cysticercosis cases, respectively¹.

Common presenting symptoms of intraocular cysticercosis, according to a cohort study by Tarun et al., which included 44 patients, were decreased visual acuity (93%), floaters (27%), ocular pain (18%), and red eye (13%), likely attributable to concurrent anterior uveitis due to the absence of ocular hypertension³. In another cohort study by Sudha and Priyanka, which included 30 cases with intraocular involvement, the initial symptoms were decreased visual acuity (100%) and floaters (3%), with no documented cases of ocular hypertension or angular closure².

The diagnosis of subretinal ocular cysticercosis requires differentiation from other conditions, such as neoplasms, subretinal abscesses, and other parasitic infections, such as toxoplasmosis or hydatid disease. Imaging techniques such as ultrasound, computed tomography, and magnetic resonance imaging play a crucial role in identifying typical cystic lesions, which, on ultrasound, usually show a hyperreflective peak attributed to the scolex or cephalic portion of the parasite, helping differentiate it from a hydatid cyst, the latter being less common and more frequently causing extraocular involvement. Serological tests, while supportive, may have limitations in specificity, requiring a comprehensive clinical and radiological approach⁵.

To date, acute angle closure has not been identified as the initial clinical presentation of subretinal cysticercosis. In our case, this was the reason for the patient's consultation. We believe that it was precipitated by the mass effect of the cyst and associated hemorrhagic retinal detachment, causing anterior displacement of the iridocorneal diaphragm, highlighting an atypical clinical presentation and a previously unreported mechanism of ocular hypertension in patients with ocular cysticercosis. Our case responded well to conventional hypotensive management.

A literature search did not find similar cases reported for subretinal presentation, finding only mechanisms described for angular closure, including pupillary blockage secondary to the mechanical effect of the cyst in the anterior chamber

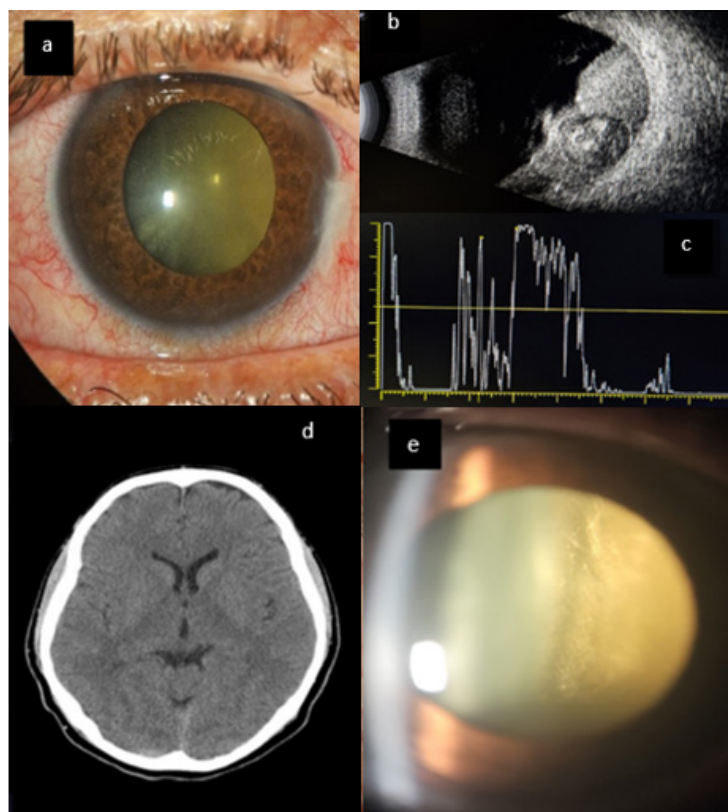


Figure 1. Slit lamp examination, Ultrasound and Tomographic Findings

(a) and (e): Photograph of the anterior segment of the right eye showing ciliary injection and medium non-reactive mydriasis with a narrow anterior chamber (a). Oblique slit lamp section shows dense vitreitis occurring after the start of albendazole therapy (e). (b), (c), and (d): Ocular ultrasound of the right eye in A and B modes showing a hemorrhagic retinal detachment involving the macular area and associated with a subretinal cystic lesion (b), which in A-mode shows a high reflectivity peak inside suggestive of scolex, findings compatible with ocular cysticercosis (c). Simple axial cranial computed tomography revealed no evidence of central nervous system involvement (d).

and two cases related to chronic inflammation caused by the presence of the cyst in the absence of treatment, leading to anterior segment neovascularization and, consequently, neovascular glaucoma^{6,7}.

The diagnosis of intraocular cysticercosis is established through clinical and image evaluation, with ultrasonography being a cost-effective, radiation-free method with sensitivity comparable to that of computed tomography for diagnosing ocular cysticercosis, in this case, determining definitively the etiology of the patient's clinical presentation¹.

Considering the size of the cyst and the morbidity associated with surgical procedures, medical management with albendazole and oral prednisolone was chosen in consultation with the patient, in line with some reports, such as that by Lim *et al.*, where a 51-year-old patient with neurocysticercosis and subretinal cysticercosis was successfully managed with albendazole and oral prednisolone, achieving a visual acuity of 20/25 in the affected eye after 2 months, with a previous visual acuity of 20/400⁸. Similarly, Singh and Singh reported a case of a 24-year-old woman who started oral

therapy with albendazole and oral prednisolone, achieving stability in visual acuity and quiescence of uveitic symptoms⁹. Additionally, García *et al.* reported the successful treatment of a subretinal macular cysticercosis case in a 25-year-old patient using praziquantel and oral prednisolone, achieving a final visual acuity of 20/30 with an initial acuity of 20/100¹⁰.

According to the reviewed protocols, although the initial recommendation is surgical management, an alternative to consider based on case complexity and patient preferences is the use of albendazole 15 mg/kg/day divided into two doses associated with oral prednisolone at a dose of 1-1.5 mg/kg/day for 6 weeks with follow-up every 1-2 weeks¹. In our case, although there was resolution of acute angular closure with improvement in symptoms and ocular hypertension, significant vitreous inflammation developed, leading to reconsideration of surgical management, which had favorable outcomes. One reason for this inflammatory progression could be the large initial size of the cyst, an aspect that we consider relevant when choosing different therapeutic strategies and which we believe can be a substrate to generate sub-analysis of present and future studies related to the treatment of this entity.

Ocular cysticercosis is a rarely reported clinical entity in Latin America, and in this case, presented with atypical acute angular closure. Ocular ultrasound is a fundamental part of the diagnostic approach. In our case, medical management was associated with significant inflammatory processes, possibly related to the initial size of the cyst, requiring surgical management, despite what has been suggested in some reports. This may be an important variable to consider when determining different therapeutic modalities. There are still clinical presentations of this entity to be identified, making timely recognition crucial for diagnosis and management to reduce the risk of visual sequelae.

Ethical considerations

Confidentiality. All protocols concerning patient confidentiality have been followed as per our institution's ethics regulations, including acquiring patient consent, written and verbal, to participate and publish this case report.

Privacy. We guarantee the patient's right to privacy.

Financing. Not applicable.

Conflict of interests. The authors have no conflict of interest to declare.

Authors' Contribution. All authors contributed to read and approved the version of the submitted manuscript.

References

1. Pujari A, Bhaskaran K, Modaboyina S, Das D, Saluja G, Samdani A, et al. Cysticercosis in ophthalmology. *Surv Ophthalmol*. 2022 Mar-Apr;67(2):544-9. doi: 10.1016/j.survophthal.2021.07.002. PMID: 34339720.
2. Ganesh SK, Priyanka. Analysis of Clinical Profile, Investigation, and Management of Ocular Cysticercosis Seen at a Tertiary Referral Centre. *Ocul Immunol Inflamm*. 2018;26(4):550-7. doi: 10.1080/09273948.2017.1413395. PMID: 29308965.
3. Sharma T, Sinha S, Shah N, Gopal L, Shanmugam MP, Bhende P, et al. Intraocular cysticercosis: clinical characteristics and visual outcome after vitreoretinal surgery. *Ophthalmology*. 2003 May;110(5):996-1004. doi: 10.1016/S0161-6420(03)00096-4. PMID: 12750103.
4. Rodríguez-Morales AJ, Yepes-Echeverri MC, Acevedo-Mendoza WF, Marín-Rincón HA, Culquichicón C, Parra-Valencia E, et al. Mapping the residual incidence of taeniasis and cysticercosis in Colombia, 2009-2013, using geographical information systems: Implications for public health and travel medicine. *Travel Med Infect Dis*. 2018 Mar-Apr; 22:51-7. doi: 10.1016/j.tmaid.2017.12.006. PMID: 29288739; PMCID: PMC5940541.
5. Otranto D, Eberhard ML. Zoonotic helminths affecting the human eye. *Parasit Vectors*. 2011 Mar 23; 4:41. doi: 10.1186/1756-3305-4-41. PMID: 21429191; PMCID: PMC3071329.
6. Chandra A, Singh MK, Singh VP, Rai AK, Chakraborty S, Maurya OP. A live cysticercosis in anterior chamber leading to glaucoma secondary to pupillary block. *J Glaucoma*. 2007 Mar;16(2):271-3. doi: 10.1097/IJG.0b013e31802d6dc2. PMID: 17473746.
7. Ratra D, Phogat C, Singh M, Choudhari N. Intravitreal cysticercosis presenting as neovascular glaucoma. *Indian J Ophthalmol*. 2010 Jan-Feb;58(1):70-3. doi: 10.4103/0301-4738.58478.
8. Lim WK, Chee SP. Nonsurgical management of subretinal cysticercosis. *Retina*. 2004 Jun;24(3):469-71. doi: 10.1097/00006982-200406000-00026. PMID: 15187678.
9. Singh J, Singh R. Submacular Parasite Masquerading as Posterior Pole Granuloma. *Case Rep Ophthalmol Med*. 2015; 2015:910383.
10. García Franco R, Arias Gómez A, Guzman Cerda J, García Roa M, Ramirez Neria P. Submacular Cysticercosis Successfully Treated through Conservative Management: Case Report. *Case Rep Ophthalmol*. 2020 Jul 7;11(2):315-21. doi: 10.1159/000508030. PMID: 32774298; PMCID: PMC7383207.